

**Effects of supplemental oxygen during endoscopy**

SC RAMRAKHA, TJ BORODY, G PANG,  
K HERDMAN, E CAMPBELL, M TORRES

Centre for Digestive Diseases, Sydney, Australia

**Aims** Study designed to document the natural level of oxygen ( $O_2$ ) saturation as levels of sedation increased during routine endoscopic procedures and the response to the supplemental  $O_2$  in the same patients using a bite block with nasal and oral supplemental oxygenation ports (Oxyguard™)

**Methods** 100 fasted patients undergoing elective panendoscopic examination were studied. All patients had a pre-anaesthetic examination including respiratory function with a peak flow meter and assigned an American Society of Anaesthesiologists (ASA) score. An endoscopist performed all examinations while an emergency physician administered the sedation agents which were a combination of midazolam, fentanyl and propofol in titrated doses. Oxyguard™ was then inserted. Patient clinical parameters were recorded as increasing depth of sedation was achieved and supplemental  $O_2$  at 4 L/min was commenced once  $O_2$  saturation reached 90%.  $O_2$  saturation was measured at 15 sec intervals.

**Results** After sedation the mean levels of arterial  $O_2$  saturation dropped significantly from baseline ( $95.7 \pm 1.9$ ) to mild ( $93.8 \pm 1.9$ ) ( $p < 0.0001$ ) and deep sedation ( $92 \pm 2\%$ ) ( $p < 0.0001$ ). In some cases  $O_2$  saturations continued to drop further to a nadir even after supplemental  $O_2$  was applied. From this point there was a time-dependent increase in  $O_2$  saturation levels. This was similar in males and females. All patients had higher oxygen saturation levels reaching baseline levels after administration of  $O_2$  via Oxyguard™ mouthpiece than those recorded before oxygenation. These levels were maintained during the endoscopic procedure, with a mean saturation level of  $95.6 \pm 1.7\%$  at 1 min ( $p = 0.68$ ). Cardiorespiratory complications were not observed with heart rate and  $ETCO_2$  levels remaining relatively constant throughout the procedure.

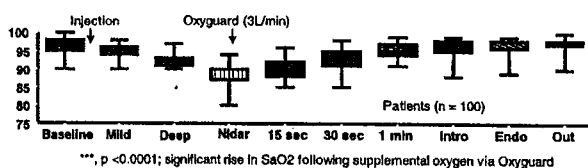


Figure 1 Oxygen saturation % before and during endoscopy

**Conclusions** Sedation caused a predictable decrease in  $O_2$ . This was similar in both males and females. Supplemental  $O_2$  via Oxyguard™ resulted in rapid recovery of  $O_2$  within 60 seconds.

**Endoscopic ultrasonography in the diagnosis of pancreatic cystic lesions**

CP DESMOND, BM DEVEREAUX

Royal Brisbane Hospital, Brisbane, Australia

**Background/Aims** Endoscopic ultrasonography (EUS) is emerging as the most useful technique for the assessment of pancreatic cystic lesions. Our aim was to describe our initial experience with EUS in patients with pancreatic cystic lesions.

**Methods** All patients with pancreatic cysts evaluated by EUS at our institution were reviewed. Demographic details, EUS findings, fine needle aspiration (FNA) results and follow-up data were collected. All procedures were conducted under conscious sedation by one endosonographer. Cyst FNA was performed with a 22-gauge needle whenever feasible. Specimen adequacy was assessed by a cytopathology technician at the time of FNA. Lesions were determined to be benign or malignant based on a combined assessment of EUS appearance, aspirate biochemistry/viscosity, presence of mucin and cyst cytology.

**Results** Between March 2002 and April 2005, 27 pancreatic cystic lesions were imaged (20% of all EUS procedures; 35% of pancreatic EUS). Mean patient age was 62 years (range 24–83 years) and 63% were female. Sixteen cysts were in the pancreatic head; 6 in the body; and 5 in the tail. The mean cyst size was 3.2 cm (range 1.2–7.8 cm); 8 were multicystic; and 10 contained septae. The pancreas demonstrated changes of chronic pancreatitis in 6 patients. FNA was performed on 21 cysts (78%) and macroscopically demonstrated mucin in 5. Microscopically, mucin was reported in 10 cases and atypical cells in 4. 90% of aspirates were considered adequate. An elevated cyst lipase ( $>1000$  U/L) was recorded in 4 patients; significantly elevated CEA ( $>192$  ng/ml) in 3 patients; and elevated CA19.9 ( $>2900$  ng/ml) in 3. Of the 4 patients with atypical cells, 2 underwent surgical resection: one for adenocarcinoma and one for insulinoma. A further patient was observed due to co-morbidities and 1 declined surgery. The benign appearing lesions were followed for a mean of 11.3 months (range 1.4–31.4 months) without a change in their benign status. Complications of FNA occurred in one patient (5%) who required overnight admission for abdominal pain. There was no evidence of pancreatitis of haemorrhage.

**Conclusions** Endoscopic ultrasonography of the pancreas with FNA is a minimally invasive, outpatient procedure with a low complication rate. It is a useful technique that provides clinically relevant information in the assessment of patients with pancreatic cystic lesions.